

Endophthalmitis Reduction with Intracameral Moxifloxacin Prophylaxis

Analysis of 600 000 Surgeries

Aravind HariPriya, MD,¹ David F. Chang, MD,² Ravilla D. Ravindran, MD¹

Purpose: To compare the postoperative endophthalmitis rate before and after initiation of intracameral (IC) moxifloxacin prophylaxis for both phacoemulsification and sutureless, manual small-incision cataract surgery (M-SICS), as well as in patients with posterior capsular rupture (PCR).

Design: Retrospective, clinical registry.

Participants: All cataract surgeries (617 453) performed during the 29-month period from January 2014 to May 2016 at the 10 regional Aravind eye hospitals were included.

Methods: The electronic health record data for all study eyes were analyzed. Endophthalmitis rates before and after moxifloxacin were statistically compared for all eyes and separately for both phacoemulsification and M-SICS, and for the eyes complicated by PCR.

Main Outcome Measures: The postoperative endophthalmitis rates before and after initiation of IC moxifloxacin prophylaxis.

Results: Overall, 302 815 eyes did not receive IC moxifloxacin and 314 638 eyes did, and there was a significant decline in the endophthalmitis rate, from 0.07% (214/302 815) to 0.02% (64/314 638) ($P < 0.001$), with moxifloxacin. For the 194 252 phacoemulsification eyes, the endophthalmitis rate was 0.07% (75/104 894) without IC moxifloxacin prophylaxis, compared with 0.01% (11/89 358) with moxifloxacin ($P < 0.001$). For the 414 657 M-SICS eyes, the endophthalmitis rate was 0.07% (135/192 149) without IC moxifloxacin prophylaxis, compared with 0.02% (52/222 508) with moxifloxacin ($P < 0.001$). Approximately half of the 8479 eyes that had PCR received IC moxifloxacin, and half did not. Without IC moxifloxacin, PCR increased the endophthalmitis rate nearly 7-fold to 0.48% (20/4186); IC moxifloxacin reduced the endophthalmitis rate with PCR to 0.21% (9/4293) ($P = 0.034$). No adverse events were due to IC moxifloxacin.

Conclusions: Routine IC moxifloxacin prophylaxis reduced the overall endophthalmitis rate by 3.5-fold (3-fold for M-SICS and nearly 6-fold for phacoemulsification). There was also a statistical benefit for eyes complicated by PCR, and IC antibiotic prophylaxis should be strongly considered for this high-risk population. These conclusions are strengthened by the high volume of cases analyzed at a single hospital network over a comparatively short time frame. Considering the association of hemorrhagic occlusive retinal vasculitis with vancomycin and the commercial unavailability of IC cefuroxime in many countries, moxifloxacin appears to be an effective option for surgeons electing IC antibiotic prophylaxis. *Ophthalmology* 2017;124:768-775 © 2017 by the American Academy of Ophthalmology



Supplemental material available at www.aaojournal.org.

The use of intracameral (IC) antibiotic prophylaxis for cataract surgery is increasing. A 2014 survey of American Society of Cataract and Refractive Surgery (ASCRS) members found that 36% of the 1147 global respondents were injecting an IC antibiotic at the conclusion of surgery compared with 14% in the 2007 survey; another 11% of the 2014 respondents planned to initiate IC injections within 6 months.^{1,2} In terms of antibiotic choice, the efficacy of IC cefuroxime for endophthalmitis prophylaxis has been confirmed by multiple retrospective studies published since the 2006 prospective, randomized European Society of Cataract & Refractive Surgeons (ESCRS) study.^{3–16} Although a commercially approved cefuroxime

formulation (Aprokam; Thea, Newcastle under Lyme, UK) is available in many European countries, it is largely unavailable outside of the European region.^{17–19} This may explain why the 2014 ASCRS survey found that cefuroxime (26%), vancomycin (37%), and moxifloxacin (33%) were comparable preferences among those using IC antibiotic prophylaxis.¹ However, unlike for cefuroxime, there is a paucity of published clinical evidence regarding the efficacy of moxifloxacin or vancomycin for IC antibiotic prophylaxis.²⁰

The Aravind Eye Care System (AECS) system is a network of 11 regional eye hospitals in southern India, which annually performs more than 260 000 cataract operations.

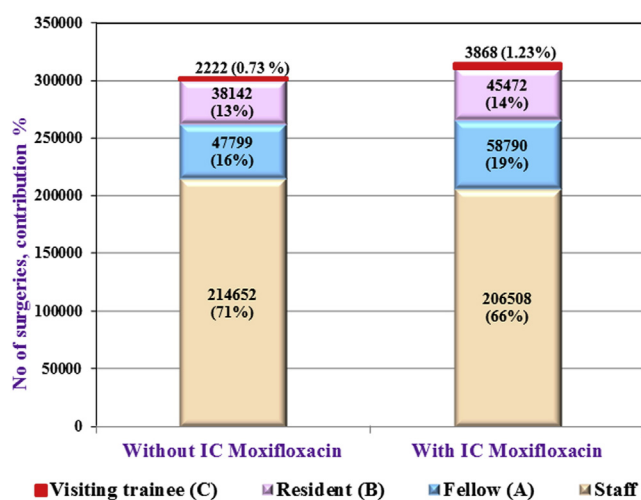


Figure 1. Percentage of surgeries performed by different surgeon categories in the 2 groups with and without intracameral (IC) moxifloxacin.

Because of the backlog of cataract blindness among poor communities in southern India, approximately 60% of our cataract surgeries are performed for little or no cost to the patient. We and others have shown that sutureless, manual small-incision cataract surgery (M-SICS) provides good outcomes at reduced cost in the developing world, and this method is used for 95% of our “charity” patients.^{21–26} Most of our “private” paying patients undergo phacoemulsification with a foldable intraocular lens (IOL). Every AECS facility uses the same standardized surgical protocols, and all outcome data are recorded in a standardized electronic record.

In an earlier study, we documented a significant reduction in the rate of infectious endophthalmitis with M-SICS after initiating routine IC moxifloxacin prophylaxis for charity patients at one of our hospitals (Madurai).²⁷ On the basis of these findings, we instituted routine IC moxifloxacin prophylaxis for all cataract surgeries throughout the entire AECS. We sought to analyze the efficacy of IC moxifloxacin prophylaxis for both phacoemulsification and M-SICS in this expanded patient population. We also sought to determine whether IC

moxifloxacin had any effect on the infection rate among those patients with vitreous loss.

Methods

Study Design

This is a retrospective, clinical registry-based study. The study protocol was conducted according to the principles described in the Declaration of Helsinki, and institutional review board/ethics committee approval was obtained. The study population comprised all charity and private patients who underwent cataract surgery between January 1, 2014, and May 31, 2016, at the 10 established regional AECS hospitals. Data from our newest center (Coimbatore, City Center), which did not open until November 2014, were not included in the analysis. The charity population included patients who were screened at outreach camps and then transported to a regional hospital for surgery, as well as those who presented to a regional hospital and underwent surgery for a small or no fee. Private patients paid market rates to undergo surgery at a regional hospital.

During the study period, all AECS patients received topical ofloxacin preoperatively and postoperatively. No IC antibiotic prophylaxis was used until August 14, 2014, when routine IC injection of 0.1 ml of moxifloxacin 0.5% w/v (Auromox; Aurolab, Tamil Nadu, India) at the conclusion of cataract surgery was instituted for all charity patients at the Madurai hospital. On the basis of a favorable preliminary analysis of endophthalmitis rates in this population, routine IC moxifloxacin prophylaxis was instituted for all patients undergoing cataract surgery at each of the other 10 AECS hospitals between April 9, 2015, and July 1, 2015. We retrospectively determined that starting in January 2014, approximately 300 000 cataract surgeries without IC moxifloxacin prophylaxis were performed within the AECS. To compare a similar number of cases performed with IC moxifloxacin prophylaxis, we included all cataract surgeries performed through May 31, 2016, in our analysis.

Auromox is manufactured by our affiliated pharmaceutical company, Aurolab, and is commercially available in India. It is also exported to countries such as Nepal, Bolivia, Azerbaijan, Madagascar, and Iraq. One milliliter of Auromox containing 5 mg of preservative-free moxifloxacin hydrochloride is packaged in sterile glass vials. The pH ranges from 6 to 7.5, the osmolality ranges from 260 to 320 mOsm, and no mixing or dilution is required. Each sterile 1-ml vial provided sufficient drug for 6 different patients by using a fresh needle and syringe to withdraw 0.1 ml from the vial for each case. The dose of moxifloxacin (0.5 mg/0.1 ml) was based on calculations targeting an anterior chamber concentration of moxifloxacin that would exceed the minimum inhibitory concentration for susceptible bacteria.²⁸

All cataract surgeries were performed using 1 of 3 methods: phacoemulsification, M-SICS, or manual large-incision extracapsular cataract extraction. The cataract procedures were performed by full-time staff, fellows, residents, and visiting trainee surgeons, representing the entire spectrum of surgeon experience.

All patients with cataract received topical ofloxacin eye drops (0.5 mg/5 ml, Auroflox Aurolab) according to a standardized regimen: every 3 hours the day before surgery and twice the morning of surgery. Topical povidone-iodine was used to prep the periorbital area and the conjunctival cul-de-sac in the operating room immediately before surgery. Topical ofloxacin drops were instilled 3 times per day for the first 15 days postoperatively. In addition, a topical combination solution of gatifloxacin (3 mg/10 ml) and dexamethasone (1 mg/10 ml) (Gatilox DM; Sun Pharma, Mumbai, India) was administered 8 times per day for the first

Table 1. Intraoperative Complication Rates in the Two Groups with and without Intracameral Moxifloxacin Prophylaxis

Type of Complication	Without IC Moxifloxacin (n = 302 815)	With IC Moxifloxacin (n = 314 638)	P Value*
PCR with IOL (no vitreous loss)	800 (0.26)	897 (0.28)	0.117
PCR with IOL with vitreous loss	2807 (0.93)	2813 (0.89)	0.173
PCR with no IOL implanted	579 (0.19)	583 (0.18)	0.592
Total	4186 (1.38)	4293 (1.36)	0.545

IC = intracameral; IOL = intraocular lens; PCR = posterior capsule rupture.

*P value between the 2 groups (chi-square/Fisher exact test).

Table 2. Comparison of Cataract Surgery Volume and Endophthalmitis Rates with and without Intracameral Moxifloxacin Prophylaxis for Each Major Regional Hospital

Hospital	Without IC Moxifloxacin		With IC Moxifloxacin		Total		P Value [†]
	Surgeries, n	Endophthalmitis Rate, n (%)	Surgeries, n	Endophthalmitis Rate, n (%)	Surgeries, n	Endophthalmitis Rate, n (%)	
Madurai	87 879	59 (0.07)	143 854	28 (0.02)	231 733	87 (0.04)	<0.001
Coimbatore	80 515	68 (0.08)	52 544	13 (0.02)	133 059	81 (0.06)	<0.001
Pondy	52 158	29 (0.06)	48 203	10 (0.02)	100 361	39 (0.04)	0.005
Tirunelveli	43 084	37 (0.09)	33 199	8 (0.02)	76 283	45 (0.06)	<0.001
6 smaller hospitals pooled*	39 179	21 (0.05)	36 838	5 (0.01)	76 017	26 (0.03)	0.003
Total (10 hospitals)	302 815	214 (0.07)	314 638	64 (0.02)	617 453	278 (0.05)	<0.001

IC = intracameral.

*Theni, Salem, Tuticorin, Udumelpet, Tirupur, and Dindigul.

[†]P value between 2 groups (chi-square/Fisher exact test).

postoperative week and then tapered over the next 4 to 6 weeks. All patients were examined on the first postoperative day and approximately 1 month postoperatively.

The AECS electronic health record system was developed internally and has been used at all of our hospitals and clinics since 2008. Along with basic demographic information, it records preoperative, intraoperative, and postoperative data for every AECS patient who undergoes cataract surgery. Additional study data were drawn from the medical records database and from microbiology department records. We reviewed and analyzed the electronic health record for any study patient with a coded diagnosis of endophthalmitis, toxic anterior segment syndrome, or corneal decompensation occurring during the 6-week postoperative period. Patients undergoing combined procedures, such as trabeculectomy or penetrating keratoplasty, were not included in the study. Patients with endogenous endophthalmitis, traumatic endophthalmitis, and endophthalmitis with onset later than 6 weeks after surgery also were excluded from the study.

The diagnosis of endophthalmitis was based on the examining ophthalmologist's clinical judgment during the normal course of postoperative care during the 6-week period immediately after surgery. The diagnosis required confirmation by a senior medical officer, who was usually the chief medical officer of the hospital when available. If endophthalmitis was suspected, a vitreous tap was performed for culture and simultaneous antibiotic injection. In some cases, a vitrectomy was performed instead of a vitreous tap.

All cases of postoperative infectious endophthalmitis reported within 6 weeks of cataract surgery were tabulated and analyzed. We compared the endophthalmitis rates between the 2 patient

populations who did and did not receive IC moxifloxacin prophylaxis. We also separately analyzed the endophthalmitis rates before and after moxifloxacin for patients undergoing phacoemulsification and for those undergoing manual extracapsular cataract extraction or M-SICS. We also evaluated endophthalmitis rates before and after moxifloxacin at each individual AECS regional hospital. Finally, a subanalysis was made of the endophthalmitis rates among patients experiencing posterior capsular rupture (PCR) who did or did not receive IC moxifloxacin.

Statistical Analysis

All analyses were carried out using SPSS statistics 17.0 STATA version 11.1 (StataCorp LP, College Station, TX). Categorical variables were expressed as a frequency (percentage). *P* < 0.05 was considered statistically significant.

Results

A total of 617 453 cataract procedures were performed at the 10 AECS regional hospitals during the 29-month study period from January 1, 2014, to May 31, 2016. Private patients accounted for 230 611 cases, and charity patients accounted for 386 842 cases. Phacoemulsification was performed in 194 252 eyes, M-SICS was performed in 414 657 eyes, and manual extracapsular cataract extraction was performed in 8544 eyes. A total of 302 815 eyes did not receive IC moxifloxacin, and 314 638 eyes did.

Staff surgeons performed relatively more procedures (71%) in the population who did not receive IC moxifloxacin compared with

Table 3. Endophthalmitis Rate without and with Intracameral Moxifloxacin for Phacoemulsification, Manual Small-Incision Cataract Surgery, and Large-Incision Extracapsular Cataract Extraction Cases

Technique	Without IC Moxifloxacin		With IC Moxifloxacin		P Value*
	Surgeries, n	Endophthalmitis Rate, n (%)	Surgeries, n	Endophthalmitis Rate, n (%)	
Phacoemulsification	104 894	75 (0.07)	89 358	11 (0.01)	<0.001
M-SICS	192 149	135 (0.07)	222 508	52 (0.02)	<0.001
ECCE	5772	4 (0.07)	2772	1 (0.036)	1.000
Total	302 815	214 (0.07)	314 638	64 (0.02)	<0.001

ECCE = extracapsular cataract extraction; IC = intracameral; M-SICS = manual small-incision cataract surgery.

Boldface indicates statistical significance.

*P value between 2 groups (chi-square/Fisher exact test).

Table 4. Endophthalmitis Rates in Eyes with Complications

Complication	Without IC Moxifloxacin		With IC Moxifloxacin		P Value*
	No. of Cases	Endophthalmitis Rate, n (%)	No. of Cases	Endophthalmitis Rate, n (%)	
PCR without vitreous loss	816	3 (0.37)	962	1 (0.10)	0.339
PCR with vitreous loss	3370	17 (0.5)	3331	8 (0.24)	0.076
Total	4186	20 (0.48)	4293	9 (0.21)	0.034

IC = intracameral; IOL = intraocular lens; PCR = posterior capsule rupture.
*P value between 2 groups (chi-square/Fisher exact test).

the population who did (66%) (Fig 1; Supplementary Table S1, available at www.aaojournal.org). Table 1 shows that both groups had comparable rates of surgical complications, such as posterior capsule rupture (PCR) and vitreous loss.

After initiating IC moxifloxacin prophylaxis, the overall AECS endophthalmitis rate declined significantly from 0.071% (214/302 815) to 0.020% (64/314 638) ($P < 0.001$). A comparable decline was observed at each of the 4 largest hospitals individually, as well as in the pooled data from the 6 lower-volume facilities (Table 2). Separate analyses showed that IC moxifloxacin led to a 3-fold reduction in endophthalmitis for M-SICS and an approximately 6-fold reduction for phacoemulsification (Table 3).

Analysis of eyes with PCR showed that 20 of 4186 eyes that did not receive moxifloxacin prophylaxis and 9 of 4293 eyes that did receive moxifloxacin prophylaxis developed endophthalmitis. Thus, IC moxifloxacin did not prevent but did significantly reduce the rate of endophthalmitis in eyes with PCR ($P = 0.034$) (Table 4).

Table 5. Culture Results for Endophthalmitis Cases with and without Intracameral Moxifloxacin

Species	Without IC Moxifloxacin, n (%)	With IC Moxifloxacin, n (%)	P Value*
Negative culture	134 (62.6)	53 (82.8)	0.003
Coagulase-negative <i>Staphylococci</i>	43 (20.1)	5 (7.8)	0.023
<i>Staphylococcus aureus</i>	1 (0.5)	1 (1.6)	0.408
<i>Streptococcus</i> species	12 (5.6)	0 (0)	0.075
Other gram-positive species†	1 (0.5)	1 (1.6)	0.408
<i>Pseudomonas aeruginosa</i>	2 (0.9)	0 (0)	1.000
Other gram-negative bacteria‡	10 (4.7)	1 (1.6)	0.466
<i>Nocardia</i> species	8 (3.7)	2 (3.1)	1.000
<i>Aspergillus flavus</i>	2 (0.9)	0 (0)	1.000
Fungal filaments	1 (0.5)	0 (0)	1.000
Atypical mycobacterium	0 (0)	1 (1.6)	0.230
Total no. of endophthalmitis cases	214	64	

IC = intracameral.

Boldface indicates statistical significance.

*P value between 2 groups (chi-square/Fisher exact test).

†Other gram-positive species: *Bacillus* species (n = 1), diphtheroids (n = 1).

‡Other gram-negative bacteria (n = 11): *Escherichia coli* (n = 2), *Aeromonas hydrophila* (n = 2), *Haemophilus* species (n = 2), *Stenotrophomonas maltophilia* (n = 2), *Moraxella* species (n = 1), *Alcaligenes denitrificans* (n = 1), *Citrobacter freundii* (n = 1).

Table 5 shows that of all the clinically diagnosed endophthalmitis cases, significantly more patients were culture positive in the group that did not receive IC moxifloxacin (80/214, 37%) compared with the group that did (11/64, 17%) ($P = 0.003$). However, Table 6 shows that both groups were comparable in terms of visual outcome at the last visit after treatment. There were no adverse events due to the IC moxifloxacin. Specifically, no instances of toxic anterior segment syndrome or corneal decompensation were thought to be caused by the IC antibiotic.

Discussion

Because postsurgical endophthalmitis is rare, a prospective, randomized, controlled clinical trial to determine the efficacy of antibiotic prophylaxis would necessitate an unfeasibly large study population. As required for the United States Food and Drug Administration approval, such a study would be extremely expensive to conduct and would need multiple study sites to generate sufficient enrollment.²⁹ In addition, treating control patients with placebo raises ethical concerns. Reflecting these obstacles, the 2006 ESCRS study is the only large prospective, randomized clinical trial that has been completed.^{3,4} To date, no drug manufacturer has submitted an application for a commercial IC antibiotic to the Food and Drug Administration for approval.

Given the impracticality of a randomized prospective trial, the efficacy of IC antibiotic prophylaxis has been evaluated through multiple retrospective clinical studies^{8–11,13–15,20} (Table 7). The majority of these reported a reduction in endophthalmitis rates with routine IC cefuroxime injection. These studies, in combination with the ESCRS prospective study, led to approval of a commercial IC cefuroxime preparation in multiple European countries (Aprokam; Thea) and an increase in the number of cataract surgeons using IC antibiotic prophylaxis.^{1,18} Reflecting the absence of any approved commercial IC antibiotic in the United States, 52% of US 2014 ASCRS survey respondents using IC antibiotics were administering vancomycin, compared with 14% using cefuroxime and 31% using moxifloxacin.¹

Because routine IC moxifloxacin prophylaxis was initiated at different time points at our various hospitals, we chose to include every consecutive cataract surgery performed throughout the entire AECS from January 1, 2014, to May 31, 2016. The 617 453 cases recorded during this period allowed comparison of more than 300 000 patients

Table 6. Corrected Distance Visual Acuity/Pinhole Vision at the Final Visit for Eyes with Endophthalmitis That Did or Did Not Receive Intracameral Moxifloxacin Prophylaxis

CDVA	Without IC Antibiotic, n (%)	With IC Moxifloxacin, n (%)	P Value*
6/6–6/18	124 (57.9)	35 (54.7)	0.644
6/24–6/60	40 (18.7)	13 (20.3)	0.772
<6/60	50 (22.9)	16 (23.5)	0.787
Total	214	64	

CDVA = corrected distance visual acuity; IC = intracameral.
*P value between 2 groups (chi-square/Fisher exact test).

who received IC moxifloxacin with more than 300 000 patients who did not. A drawback of nonrandomized retrospective trials is the potential for covariables to influence the results. Longer clinical trial periods generate more surgical cases but also increase the chance that differences in surgical techniques or in surgeon and patient populations could affect the infection rate. Because the largest retrospective studies have encompassed periods ranging from 4 to 14 years (Table 7), our study is unique in analyzing more than 600 000 consecutive surgeries from a multicenter institution during a period of only 29 months. Totaling this many surgeries over so short a time reduces the chance that other factors could have improved the endophthalmitis rates.

Pooling data from multiple hospitals may introduce more variables. However, the cataract surgical protocols, instrumentation, and techniques are standardized throughout all of the different AECS surgical facilities. Every AECS hospital uses the same operative drugs, irrigating solutions, viscoelastic, blades, and IOLs from the same manufacturers. Such standardization reduces potential covariables and is generally lacking in other published multicenter studies. Another potential variable is in how endophthalmitis is diagnosed

and reported, and all AECS facilities use an identical electronic health record system. The uniformity of our electronic health record reporting protocols provides a large real-time registry through which we continuously monitor clinical outcomes and specific complications such as endophthalmitis and toxic anterior segment syndrome. We also looked at individual endophthalmitis rates for each of the 91 surgeons performing at least 2000 surgeries during the study period and did not find that any single individual's results skewed the overall composite rates.

This study confirms and expands on our preliminary findings from a single hospital (Madurai) that routine IC moxifloxacin prophylaxis is effective for patients undergoing M-SICS.²⁷ This technique accounts for a large volume of cataract surgery in developing countries where the backlog of cataract blindness necessitates a method that is cost-effective and safer for advanced white and brunescant cataracts, particularly in the hands of less-experienced surgeons.^{21–26,30,31} This indigent population has additional risk factors for infectious endophthalmitis, such as the use of larger sutureless incisions to accommodate inexpensive polymethylmethacrylate IOLs. Patient hygiene and compliance with topical antibiotics and postoperative follow-up may be poor. Many disposable supplies, such as gloves, gowns, tubing, irrigation bottles, and cannulae, are reused to further reduce costs.³² Despite numerous cost-saving practices that would not be allowed in North America or Western Europe, our study shows that the endophthalmitis rate in this higher-risk charity population can be lowered to 0.02% with IC moxifloxacin. Consistent with a meta-analysis of the cefuroxime literature,³³ our previous study found that the additional cost of routine IC moxifloxacin prophylaxis was offset by the savings realized through a reduction in endophthalmitis cases requiring treatment.^{15,27}

The 3.5-fold decrease in the endophthalmitis rate is highly significant, and to our knowledge makes this one of the largest single institution studies to demonstrate the

Table 7. Most Recent Retrospective Studies Comparing Endophthalmitis Rates with and without Intracameral Antibiotic (Published Since 2012)

Reference	IC Antibiotic Used	Without IC Antibiotic			With IC Antibiotic			Country	Duration (years)	Total (N)
		Surgeries (N)	POE (N)	POE Rate (%)	Surgeries (N)	POE (N)	POE Rate (%)			
Tan et al, ⁸ 2012	Cefazolin	29 539	19	0.064	20 638	2	0.01	Singapore	11	50 177
Barreau et al, ⁹ 2012	Cefuroxime	2826	35	1.24	2289	1	0.04	France	5	5115
Rodríguez-Caravaca et al, ¹¹ 2013	Cefuroxime	6595	39	0.59	12 868	5	0.039	Spain	14	19 463
Friling et al, ¹⁰ 2013†	Multiple*	2804	11	0.39	461 951	123	0.027	Sweden	6	464 755
Matsuura et al, ²⁰ 2013†	Moxifloxacin	15 958	8	0.05	18 794	3	0.01	Japan	4	34 752
Herrinton et al, ¹⁵ 2016	Cefazolin	237 709	187	0.07	63 241	28	0.04	California	8	300 950
Jabbarvand et al, ¹³ 2016	Cefuroxime	193 440	28	0.014	25 920	0	0	Iran	9	219 360
Daien et al, ¹⁴ 2016†	Cefuroxime	1 479 158	1393	0.09	954 850	548	0.06	France	5	24 34 008
Current study	Moxifloxacin	303 244	218	0.07	315 383	68	0.02	India	2.5	618 627
Total		2 271 273	1938	0.08	187 5934	778	0.04			4 147 207

IC = intracameral; POE = postoperative endophthalmitis.
*Cefuroxime (99%), moxifloxacin (1%).
†National database.

efficacy of IC antibiotic prophylaxis. Moxifloxacin is a fourth-generation fluoroquinolone with a broad spectrum of coverage that includes both gram-positive and gram-negative bacteria, and many anaerobes. The high aqueous concentration achieved by an IC injection should be highly effective against sensitive organisms because moxifloxacin's bactericidal efficacy is concentration dependent.²⁸ One study estimated that injecting 0.5 mg in 0.1 ml of moxifloxacin would exceed the median minimum inhibitory concentration of most endophthalmitis pathogens by 300-fold.^{26,34,35} Additional studies have supported the safety of moxifloxacin for IC prophylaxis.^{20,34–38}

Fluoroquinolone resistance rates among coagulase-negative *Staphylococcus endophthalmitis* isolates have been reported to be as high as 40% to 60%.³⁹ However, in this study, IC moxifloxacin prophylaxis significantly reduced the number of infections caused by coagulase-negative *Staphylococcus*, which is the most common pathogen in our patient population (Table 5). It is possible that the extremely high aqueous concentration achieved by direct IC injection was still effective because moxifloxacin's bactericidal efficacy is concentration dependent. This efficacy also could reflect geographic differences in the causative organisms and their antibiotic sensitivity profiles. Our culture results also showed that IC moxifloxacin was effective in reducing infections caused by *Streptococcus*, *Nocardia*, and gram-negative bacteria, all of which can cause highly virulent forms of endophthalmitis. Data from a Swedish registry showed that cefuroxime was less effective against gram-negative bacteria, and some of those surgeons reported switching to moxifloxacin because of its broader spectrum of activity.¹⁰

These efficacy data are particularly important for countries where no commercial IC antibiotic formulation is available, and antibiotics are being mixed or compounded, or withdrawn from unpreserved topical bottles.^{1,19,34,35,38} Although IC vancomycin was the most popular antibiotic chosen for intraocular prophylaxis in both the 2007 and 2014 ASCRS surveys, new evidence regarding its association with hemorrhagic occlusive retinal vasculitis has led many surgeons to seek an alternative.^{1,2,40} Therefore, our new finding that IC moxifloxacin prophylaxis is highly efficacious for phacoemulsification is timely and important.

In terms of risk factors for endophthalmitis, trainee surgeons performed a slightly higher percentage of cases in the group receiving IC moxifloxacin, and so the improvement in this group cannot be due to more favorable surgeon selection. Posterior capsular rupture and vitreous loss significantly increase the risk of endophthalmitis, but there were no differences in the rate of these complications between the 2 groups⁴¹ (Table 4). In what to our knowledge is one of the largest comparison studies to date, we found that PCR, with or without vitreous loss, caused an approximately 7-fold increase in endophthalmitis in the absence of IC antibiotic. However, by comparing more than 4000 of these complicated eyes in each group, we found a statistically significant reduction in endophthalmitis with the injection of IC moxifloxacin at the end of surgery.

In conclusion, this is the one of the largest retrospective studies to show the efficacy of IC moxifloxacin prophylaxis, with a 3.5-fold reduction in the overall rate of endophthalmitis despite using the same standardized topical antibiotic regimen in all patients. Our data support the efficacy of moxifloxacin as an option for those surgeons using IC prophylaxis for phacoemulsification or M-SICS. This study does not constitute level I evidence, however, and there is no consensus that IC antibiotic prophylaxis should be the standard of care.^{42,43} Nevertheless, we believe that for the many surgeons who have not adopted routine IC antibiotic prophylaxis, this should be considered for higher-risk eyes experiencing PCR with vitreous loss.

Acknowledgments. The authors thank the following chief medical officers for sharing data from their respective regional hospitals: Dr. R. Ramakrishnan (Aravind, Thirunelveli), Dr. V. Narendran (Aravind, Coimbatore), Dr. Rengaraj Venkatesh (Aravind, Pondicherry), Dr. Dipankar Datta (Aravind, Theni), and Dr. Manohar Babu (Aravind, Salem). The authors also thank Dr. Prajna Lalitha (Aravind, Madurai), who helped in analyzing the culture results.

References

1. Chang DF, Braga-Mele R, Henderson BA, et al. Antibiotic prophylaxis of postoperative endophthalmitis after cataract surgery: results of the 2014 ASCRS member survey. *J Cataract Refract Surg.* 2015;41:1300-1305.
2. Chang DF, Braga-Mele R, Mamalis N, et al. Prophylaxis of postoperative endophthalmitis after cataract surgery: results of the 2007 ASCRS member survey. *J Cataract Refract Surg.* 2007;33:1801-1805.
3. Barry P, Seal DV, Gettinby G, et al. ESCRS study of prophylaxis of postoperative endophthalmitis after cataract surgery: preliminary report of principal results from a European multicenter study. *J Cataract Refract Surg.* 2006;32:407-410.
4. Endophthalmitis Study Group, European Society of Cataract & Refractive Surgeons. Prophylaxis of postoperative endophthalmitis following cataract surgery: results of the ESCRS multicenter study and identification of risk factors. *J Cataract Refract Surg.* 2007;33:978-988.
5. Lundström M, Wejde G, Stenevi U, et al. Endophthalmitis after cataract surgery: a nationwide prospective study evaluating incidence in relation to incision type and location. *Ophthalmology.* 2007;114:866-870.
6. García-Sáenz MC, Arias-Puente A, Rodríguez-Caravaca G, et al. Effectiveness of intracameral cefuroxime in preventing endophthalmitis after cataract surgery. Ten-year comparative study. *J Cataract Refract Surg.* 2010;36:203-207.
7. Behndig A, Montan P, Stenevi U, et al. One million cataract surgeries: Swedish National Cataract Register 1992-2009. *J Cataract Refract Surg.* 2011;37:1539-1545.
8. Tan CSH, Wong HK, Yang FP. Epidemiology of postoperative endophthalmitis in an Asian population: 11-year incidence and effect of intracameral antibiotic agents. *J Cataract Refract Surg.* 2012;38:425-430.
9. Barreau G, Mounier M, Marin B, et al. Intracameral cefuroxime injection at the end of cataract surgery to reduce the incidence of endophthalmitis: French study. *J Cataract Refract Surg.* 2012;38:1370-1375.

10. Friling E, Lundström M, Stenevi U, et al. Six-year incidence of endophthalmitis after cataract surgery: Swedish national study. *J Cataract Refract Surg.* 2013;39:15-21.
11. Rodríguez-Caravaca G, García-Sáenz MC, Villar-Del-Campo MC, et al. Incidence of endophthalmitis and impact of prophylaxis with cefuroxime on cataract surgery. *J Cataract Refract Surg.* 2013;39:1399-1403.
12. Shorstein NH, Winthrop KL, Herrinton LJ. Decreased postoperative endophthalmitis rate after institution of intracameral antibiotics in a Northern California eye department. *J Cataract Refract Surg.* 2013;39:8-14.
13. Jabbarvand M, Hashemian H, Khodaparast M, et al. Endophthalmitis occurring after cataract surgery: outcomes of more than 480 000 cataract surgeries, epidemiologic features, and risk factors. *Ophthalmology.* 2016;123:295-301.
14. Daien V, Papinaud L, Gillies MC, et al. Effectiveness and safety of an intracameral injection of cefuroxime for the prevention of endophthalmitis after cataract surgery with or without perioperative capsular rupture. *JAMA Ophthalmol.* 2016;134:810-816.
15. Herrinton LJ, Shorstein NH, Paschal JF, et al. Comparative effectiveness of antibiotic prophylaxis in cataract surgery. *Ophthalmology.* 2016;123:287-294.
16. Creuzot-Garcher C, Benzenine E, Mariet AS, et al. Incidence of acute postoperative endophthalmitis after cataract surgery: a nationwide study in France from 2005 to 2014. *Ophthalmology.* 2016;123:1414-1420.
17. Barry P, Cordovés L, Gardner S. *ESCRS Guidelines for Prevention and Treatment of Endophthalmitis Following Cataract Surgery: Data, Dilemmas and Conclusions.* Dublin, Ireland: European Society of Cataract and Refractive Surgeons; 2013. Available at <http://www.es CRS.org/downloads/Endophthalmitis-Guidelines.pdf>. Accessed August 5, 2016.
18. Barry P. Adoption of intracameral antibiotic prophylaxis of endophthalmitis following cataract surgery: update on the ESCRS Endophthalmitis Study. *J Cataract Refract Surg.* 2014;40:138-142.
19. Braga-Mele R, Chang DF, Henderson BA, et al. Intracameral antibiotics: safety, efficacy, and preparation. *J Cataract Refract Surg.* 2014;40:2134-2142.
20. Matsuura K, Miyoshi T, Suto C, et al. Efficacy and safety of prophylactic intracameral moxifloxacin injection in Japan. *J Cataract Refract Surg.* 2013;39:1702-1706.
21. Muralikrishnan R, Venkatesh R, Prajna NV, et al. Economic cost of cataract surgery procedures in an established eye care centre in Southern India. *Ophthalmic Epidemiol.* 2004;11:369-380.
22. Venkatesh R, Muralikrishnan R, Balent LC, et al. Outcomes of high volume cataract surgeries in a developing country. *Br J Ophthalmol.* 2005;89:1079-1083.
23. Ruit S, Tabin G, Chang D, et al. A prospective randomized clinical trial of phacoemulsification vs manual sutureless small-incision extracapsular cataract surgery in Nepal. *Am J Ophthalmol.* 2007;143:32-38.
24. Aravind S, HariPriya A, Sumara Taranum BS. Cataract surgery and intraocular lens manufacturing in India. *Curr Opin Ophthalmol.* 2008;19:60-65.
25. Khanna R, Pujari S, Sangwan V. Cataract surgery in developing countries. *Curr Opin Ophthalmol.* 2011;22:10-14.
26. Venkatesh R, Chang DF, Muralikrishnan R, et al. Manual small incision cataract surgery: a review. *Asia Pac J Ophthalmol (Phila).* 2012;1:113-119.
27. HariPriya A, Chang DF, Namburur S, et al. Efficacy of intracameral moxifloxacin endophthalmitis prophylaxis at Aravind Eye Hospital. *Ophthalmology.* 2016;123:302-308.
28. O'Brien TP, Arshinoff SA, Mah FS. Perspectives on antibiotics for postoperative endophthalmitis prophylaxis: potential role of moxifloxacin. *J Cataract Refract Surg.* 2007;33:1790-1800.
29. Javitt JC. Intracameral antibiotics reduce the risk of endophthalmitis after cataract surgery: does the preponderance of the evidence mandate a global change in practice? *Ophthalmology.* 2016;123:226-231.
30. HariPriya A, Chang DF, Reena M, et al. Complication rates of phacoemulsification and manual small-incision cataract surgery at Aravind Eye Hospital. *J Cataract Refract Surg.* 2012;38:1360-1369.
31. Venkatesh R, Tan CSH, Singh GP, et al. Safety and efficacy of manual small incision cataract surgery for brunescant and black cataracts. *Eye (Lond).* 2009;23:1155-1157.
32. Ravindran RD, Venkatesh R, Chang DF, et al. Incidence of post-ataract endophthalmitis at Aravind Eye Hospital: outcomes of more than 42,000 consecutive cases using standardized sterilization and prophylaxis protocols. *J Cataract Refract Surg.* 2009;35:629-636.
33. Linertová R, Abreu-González R, García-Pérez L, et al. Intracameral cefuroxime and moxifloxacin used as endophthalmitis prophylaxis after cataract surgery: systematic review of effectiveness and cost-effectiveness. *Clin Ophthalmol.* 2014;8:1515-1522.
34. Lane SS, Osher RH, Masket S, et al. Evaluation of the safety of prophylactic intracameral moxifloxacin in cataract surgery. *J Cataract Refract Surg.* 2008;34:1451-1459.
35. Arshinoff SA, Modabber M. Dose and administration of intracameral moxifloxacin for prophylaxis of postoperative endophthalmitis. *J Cataract Refract Surg.* 2016;42(12):1730-1741.
36. Matsuura K, Suto C, Akura J, et al. Comparison between intracameral moxifloxacin administration methods by assessing intraocular concentrations and drug kinetics. *Graefes Arch Clin Exp Ophthalmol.* 2013;251:1955-1959.
37. Ekinçi Koktekir B, Aslan BS. Safety of prophylactic intracameral moxifloxacin use in cataract surgery. *J Ocul Pharmacol Ther.* 2012;28:278-282.
38. Arbisser LB. Safety of intracameral moxifloxacin for prophylaxis of endophthalmitis after cataract surgery. *J Cataract Refract Surg.* 2008;34:1114-1120.
39. Schimel AM, Miller D, Flynn HW. Endophthalmitis isolates and antibiotic susceptibilities: a 10-year review of culture-proven cases. *Am J Ophthalmol.* 2013;156:50-52.e1.
40. Witkin AJ, Chang DF, Jumper JM, et al. Vancomycin-associated hemorrhagic occlusive retinal vasculitis: clinical characteristics of 36 eyes. *Ophthalmology.* 2017;124:583-595.
41. Cao H, Zhang L, Li L, et al. Risk factors for acute endophthalmitis following cataract surgery: a systematic review and meta-analysis. *PLoS One.* 2013;8:e71731.
42. Schwartz SG, Flynn HW, Grzybowski A, et al. Intracameral antibiotics and cataract surgery: endophthalmitis rates, costs, and stewardship. *Ophthalmology.* 2016;123:1411-1413.
43. Spellberg B, Srinivasan A, Chambers HF. New societal approaches to empowering antibiotic stewardship. *JAMA.* 2016;22(315):1229-1230.

Footnotes and Financial Disclosures

Originally received: August 8, 2016.

Final revision: January 12, 2017.

Accepted: January 17, 2017.

Available online: February 14, 2017.

Manuscript no. 2016-44.

¹ Aravind Eye Hospital, Madurai, India.

² Altos Eye Physicians, Los Altos, California.

Financial Disclosure(s):

The author(s) have no proprietary or commercial interest in any materials discussed in this article.

Author Contributions:

Conception and design: Haripriya, Chang

Data collection: Haripriya, Ravindran

Analysis and interpretation: Haripriya, Chang, Ravindran

Obtained funding: Not applicable

Overall responsibility: Haripriya, Chang

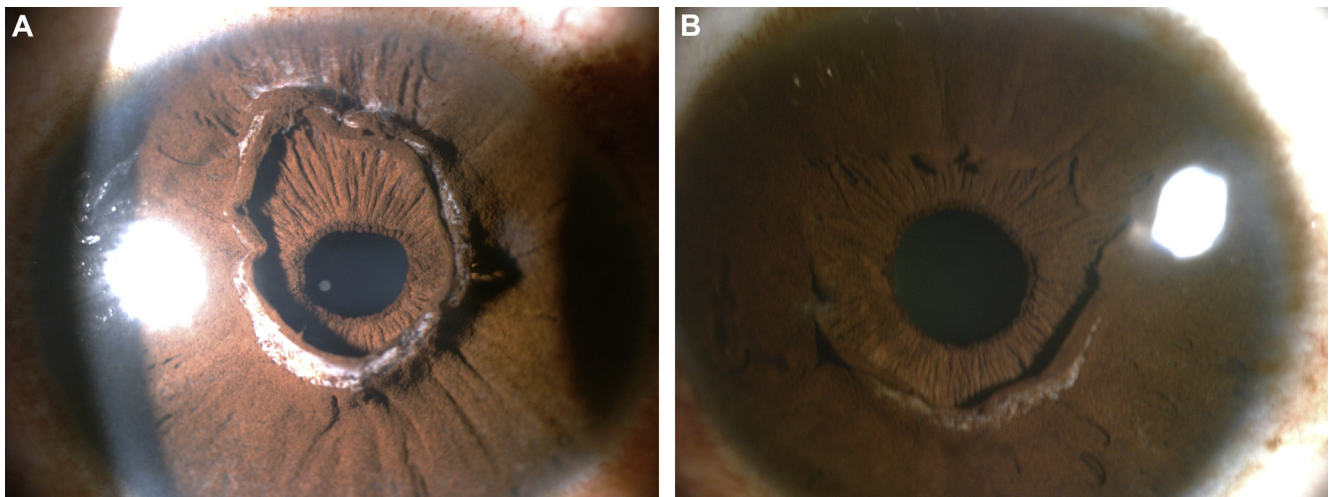
Abbreviations and Acronyms:

AECS = Aravind Eye Care System; **ASCRS** = American Society of Cataract and Refractive Surgery; **ESCRS** = European Society of Cataract & Refractive Surgeons; **IC** = intracameral; **IOL** = intraocular lens; **M-SICS** = manual small-incision cataract surgery; **PCR** = posterior capsular rupture.

Correspondence:

Aravind Haripriya, MD, Aravind Eye Hospital, 1, Anna Nagar, Madurai 625020, India. E-mail: haripriya@aravind.org.

Pictures & Perspectives



A Pseudopupil: Anterior Iris Stroma Hyperplasia

A 42-year-old African-American man presented for a routine examination, with no visual complaints. Slit-lamp microscopic examination of both eyes showed redundancy of the iris tissue arising from the collarettes. This pseudopupil was nonresponsive to mydriatics. Gonioscopic examination revealed no abnormalities of the angle. This anomaly is thought to arise from aberrant degeneration of the anterior tunica vasculosa lentis, which usually begins to resorb at 6 months during embryogenesis (Fig 1A, right eye; Fig 1B, left eye).

MATHIEU F. BAKHOUM, MD, PhD^{1,2}

JOHN M. ALEXANDER, MD^{1,2}

HENRY D. PERRY, MD^{1,3}

¹Nassau University Medical Center, Department of Ophthalmology, East Meadow, New York; ²Columbia University Medical Center, Department of Ophthalmology, New York, New York; ³Ophthalmic Consultants of Long Island, Long Island, New York